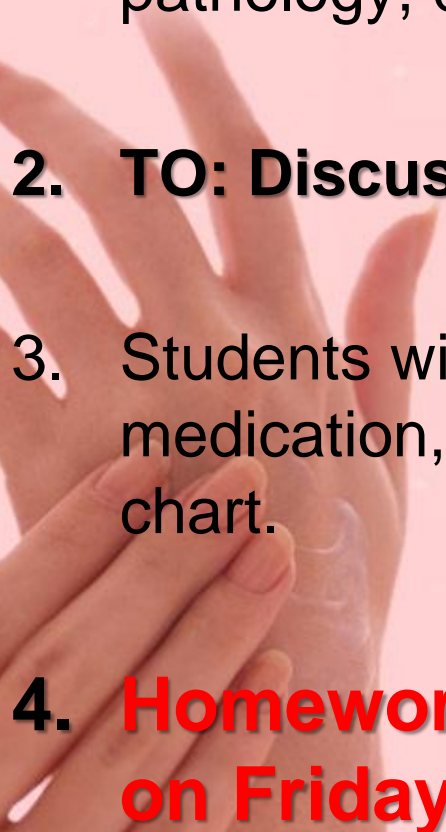
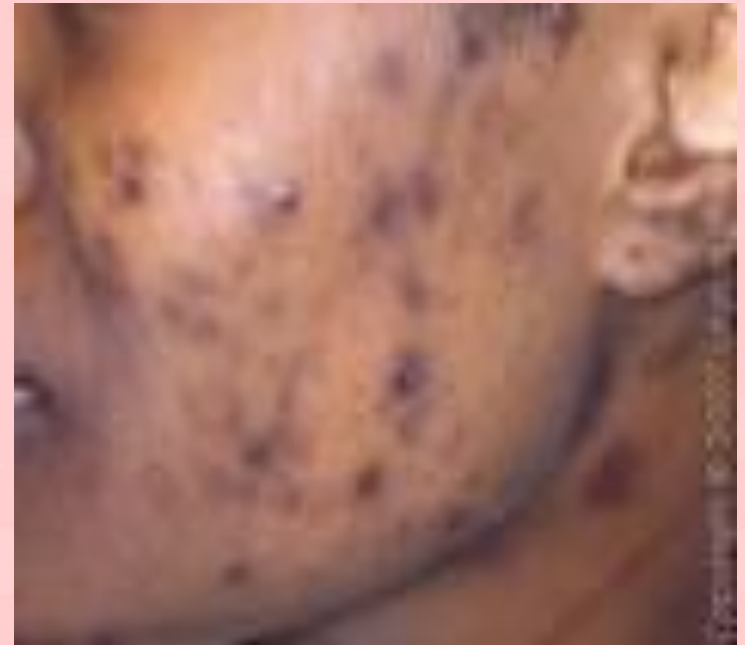
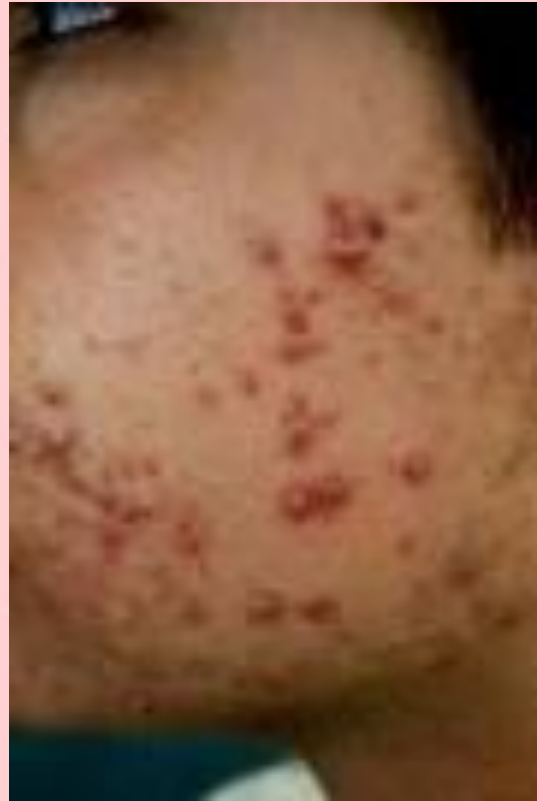
Today's Agenda: 9/3/14

1. Students will highlight standard: 1.4 Describe common diseases and disorders of each body system (prevention, pathology, diagnosis, and treatment).
 2. **TO: Discuss 9 common integumentary pathologies.**
 3. Students will research for each pathology prevention, medication, and epidemiology in order to complete given chart.
 4. **Homework – study for an Integumentary quiz on Friday; will need to be able to label.**
- 

1. Acne: inflammation of the sebaceous glands.



Acne Continued

- Et:

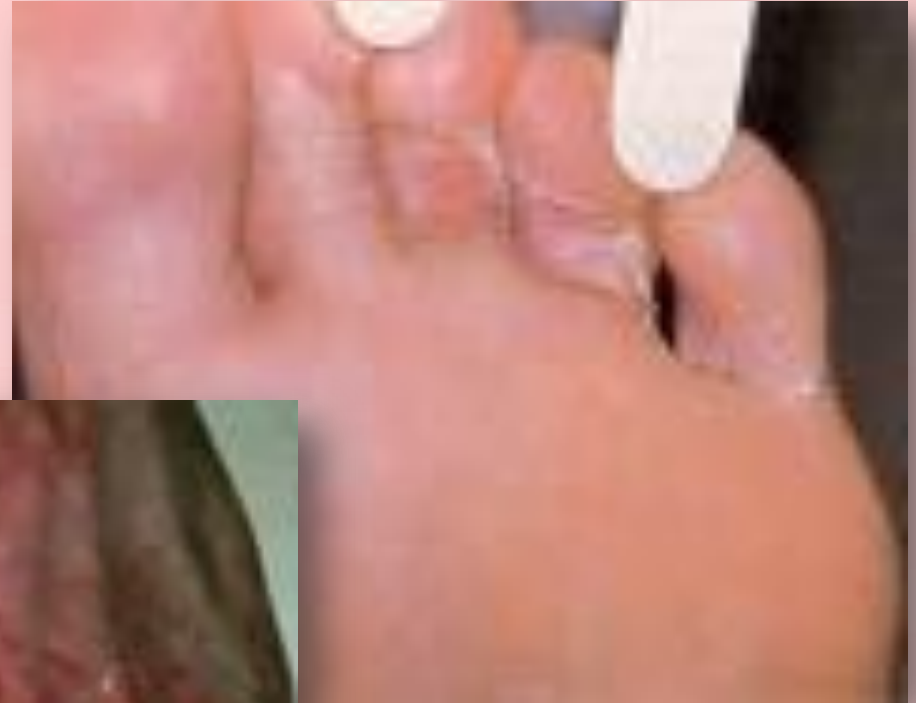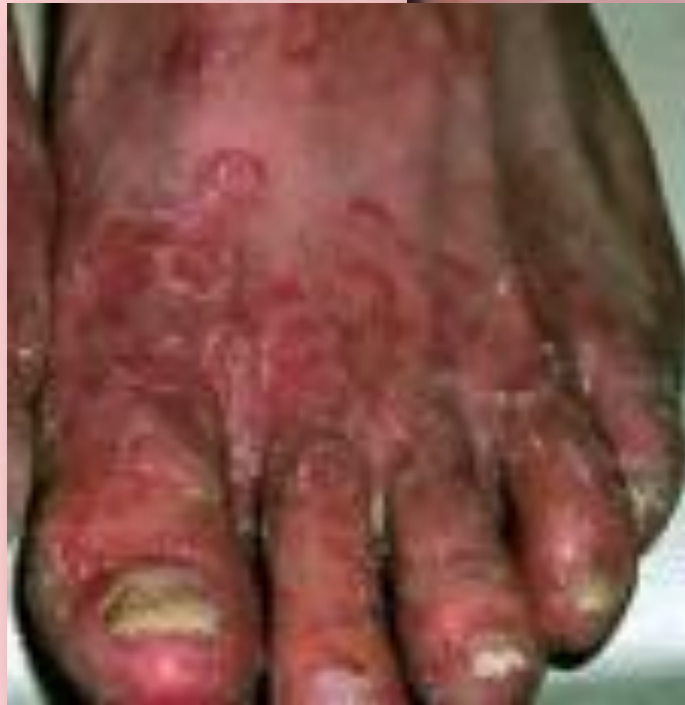- Hair follicles become blocked with dirt
- Cosmetics
- Excess oil
- Bacteria

- Tx:

- Skin washing
- Avoiding creams or heavy make-up
- Antibiotics
- UV light tx



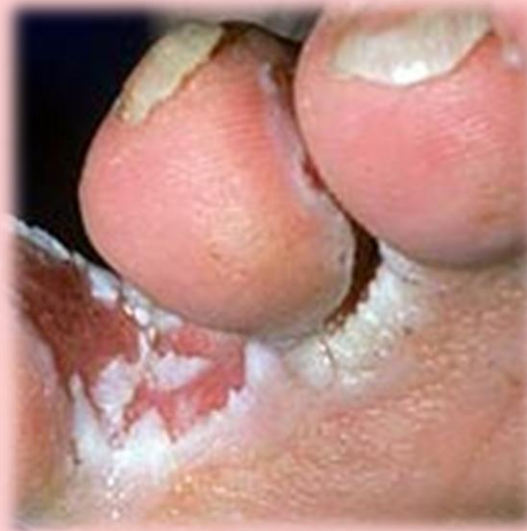2. Athlete's Foot - A contagious fungal inf



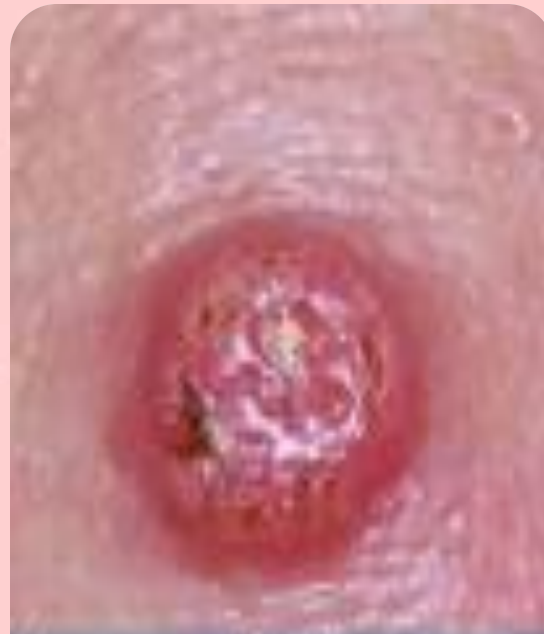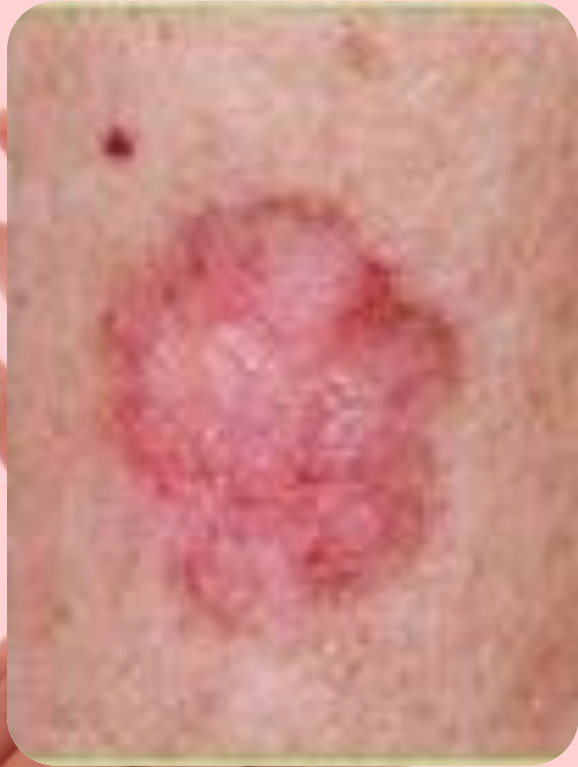Athlete's Foot Continued

- s/s:
 - Itching
 - Blisters
 - Cracking skin
 - Open sores

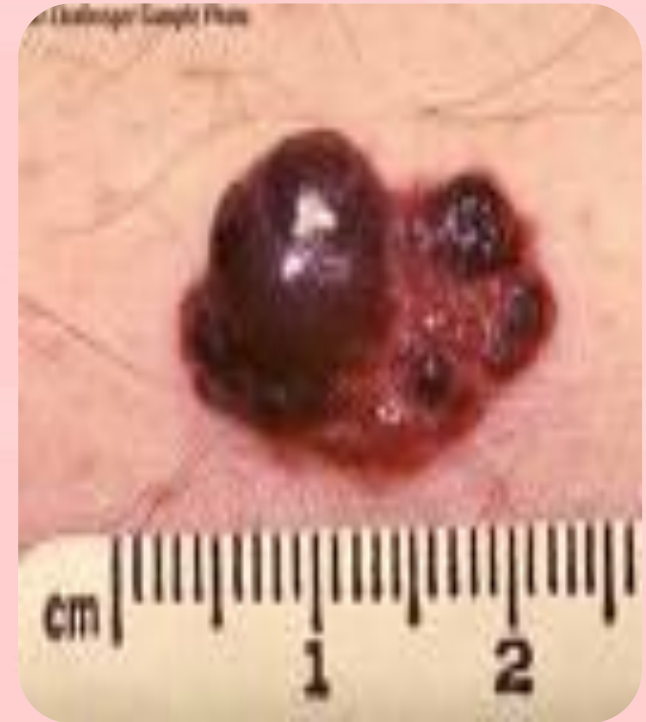- Tx:
 - Antifungal meds
 - Keep area dry & clean.



3. Skin CA – Basal cell, squamous cell & malignant melanoma.



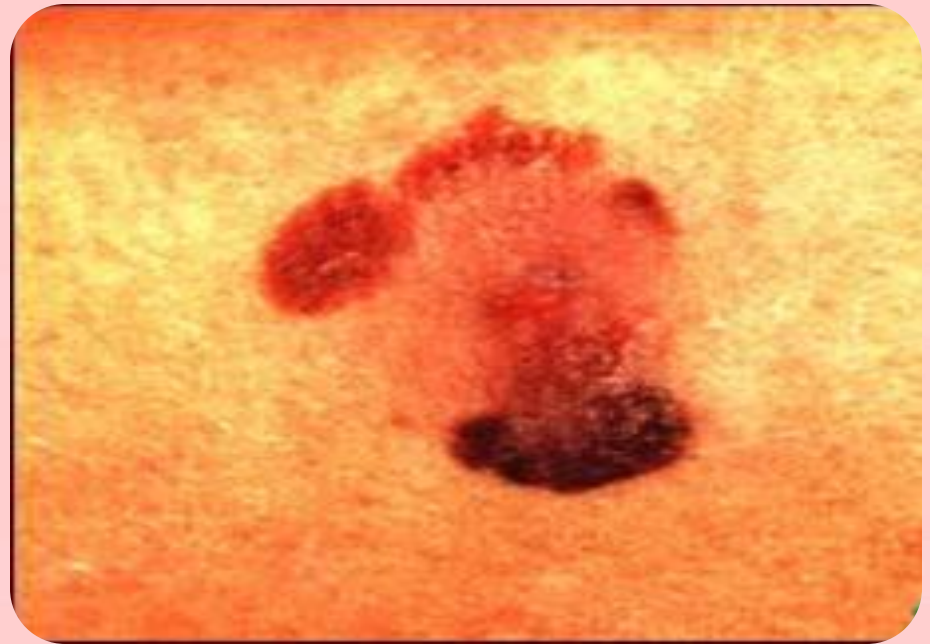Squamous Cell Carcinoma



Skin CA

- s/s:
 - From a mole that changes color, size, shape, or texture
 - Bleeding or itching mole
- Et:
 - Sun, tanning beds
 - Irritating chemicals
 - Radiation

- Tx:
 - Surgical removal
 - Radiation



Benign

Malignant

A. Asymmetry

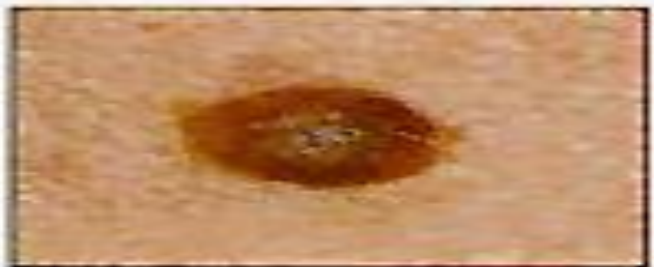

Symmetrical



Asymmetrical

B. Border

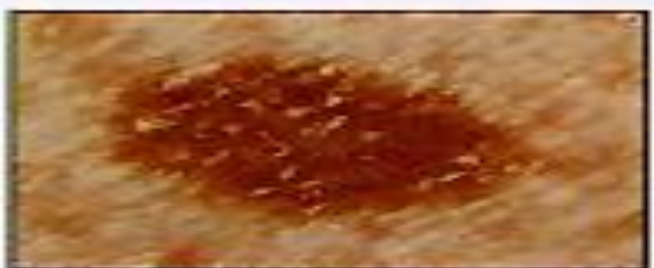


Even edges



Uneven edges

C. Color



One shade

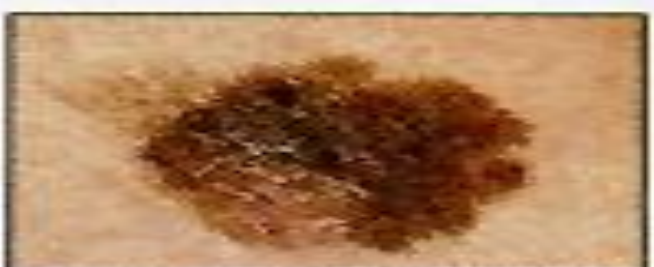

Two or more shades

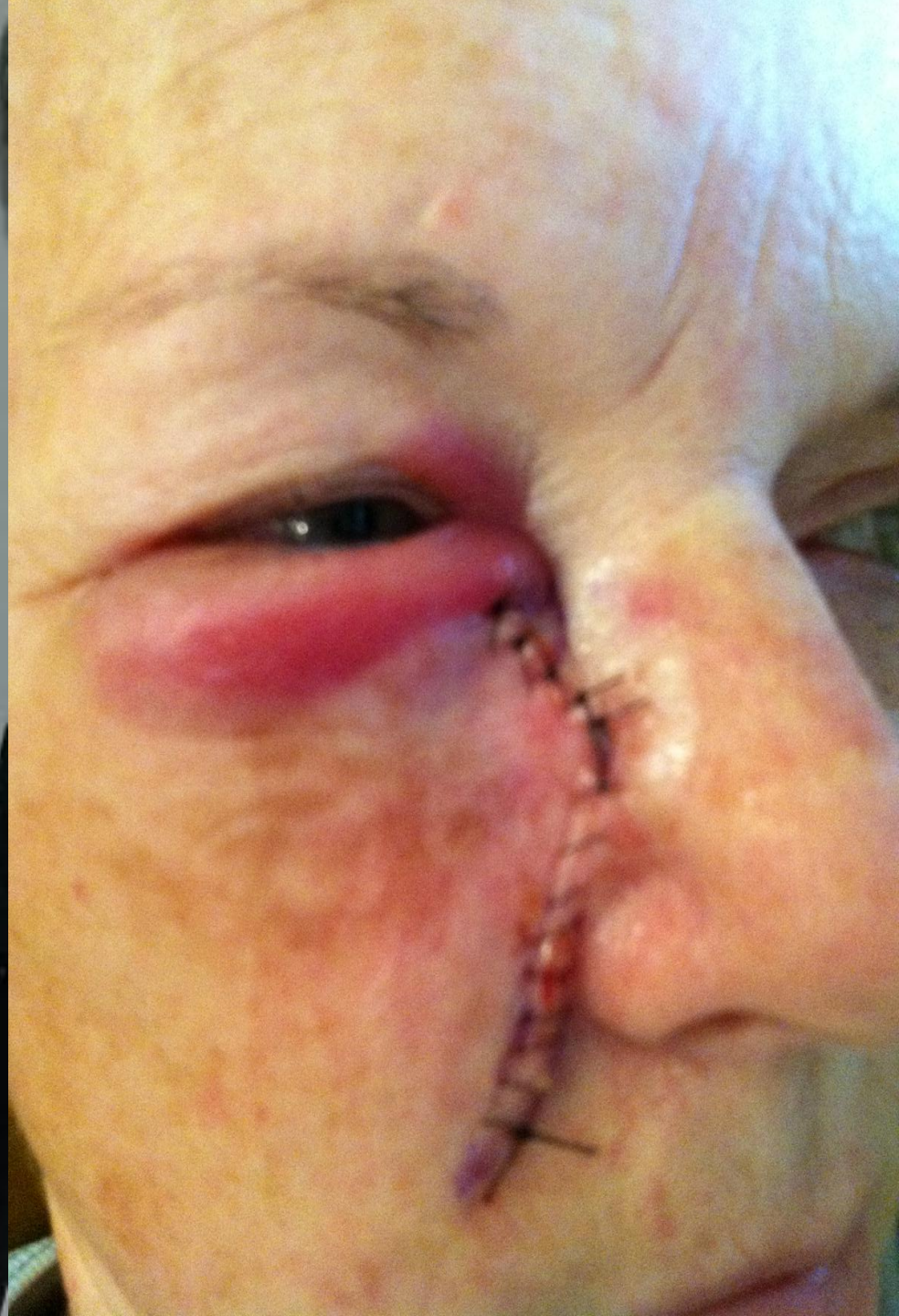D. Diameter



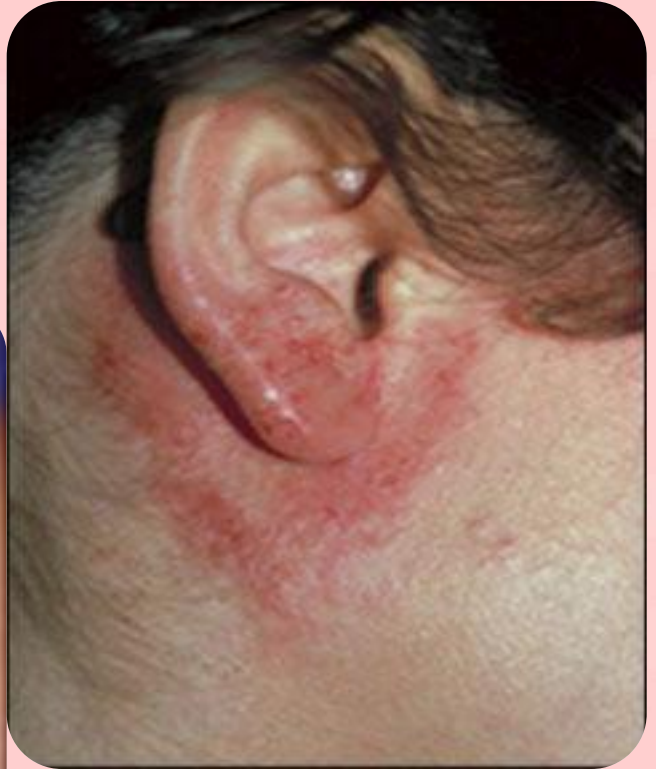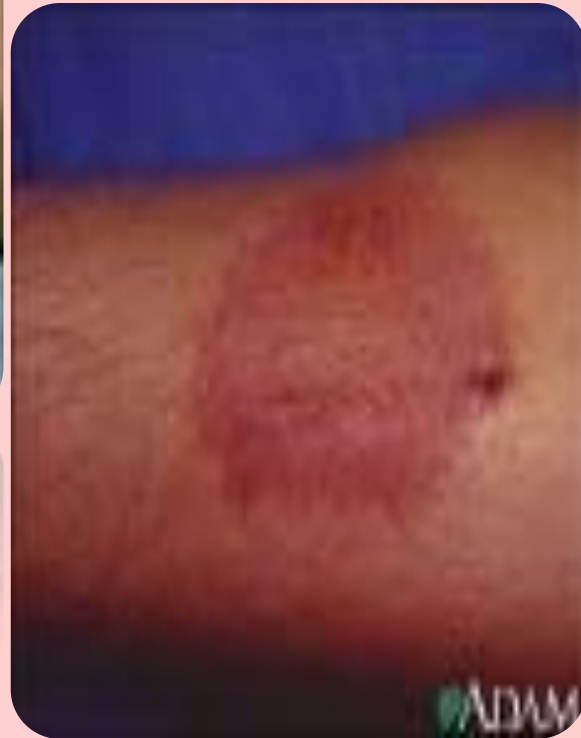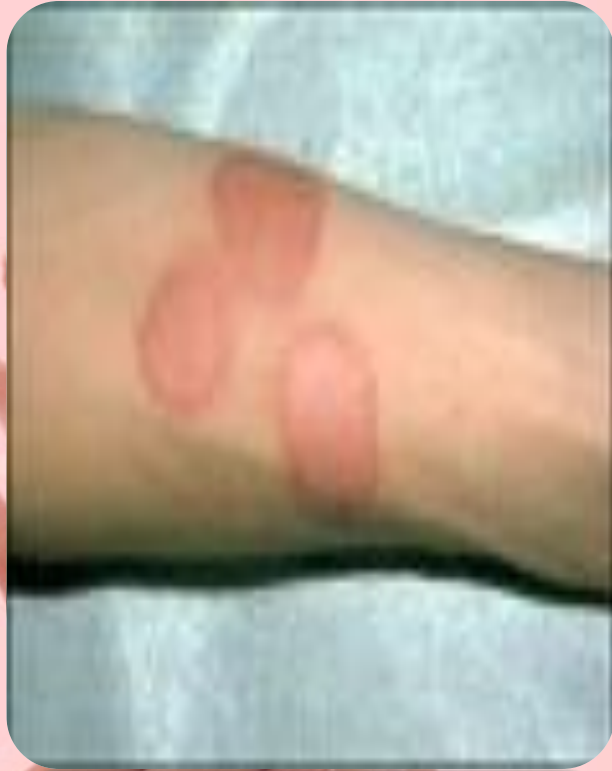Smaller than 6 mm



Larger than 6 mm



4. Dermatitis – An inflammation of the skin.



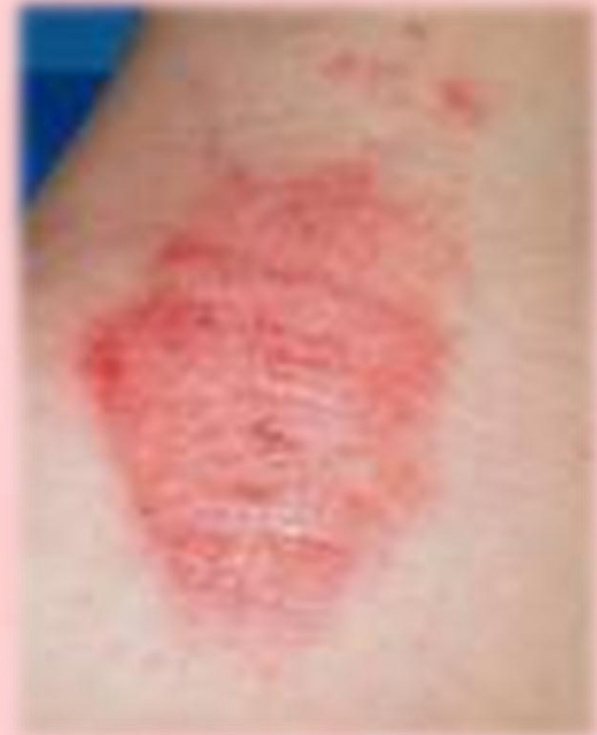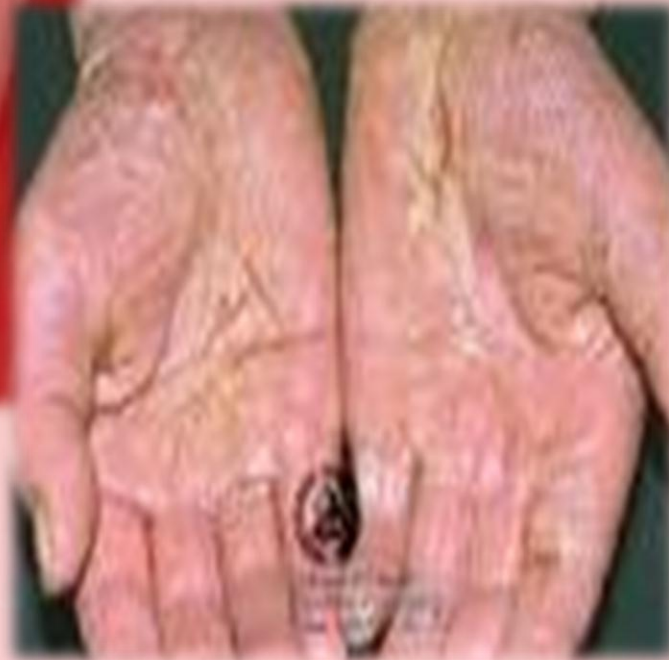Dermatitis Continued

- Et:
 - Any substance that irritates the skin
 - Detergents
 - Cosmetics
 - Pollen
 - Foods
 - Poison ivy, oak, sumac
- s/s:
 - Dry skin, itching
 - Erythema
 - Edema, scaling

- Tx:
 - Eliminating cause
 - Anti-inflammatory ointments
 - Antihistamines
 - Steroids

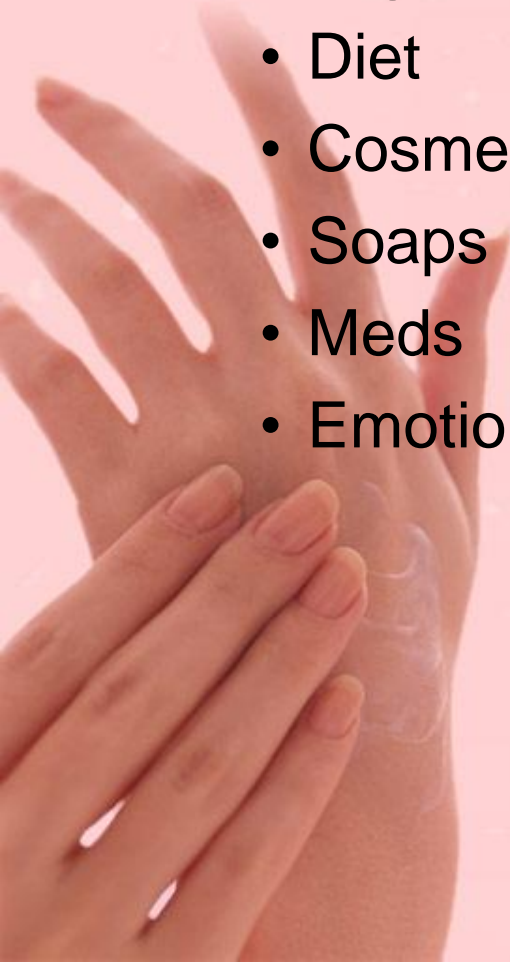

5. Eczema – A noncontagious, inflammatory skin disorder caused by an allergen.

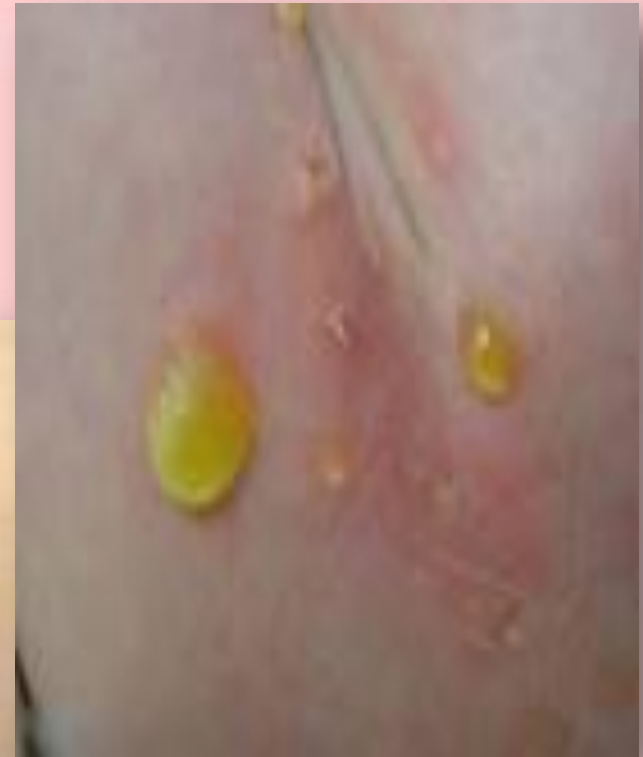
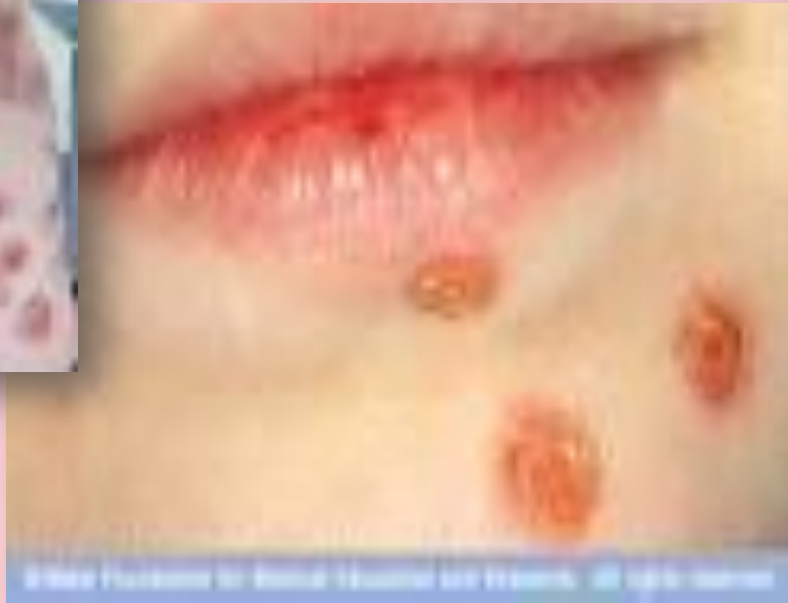
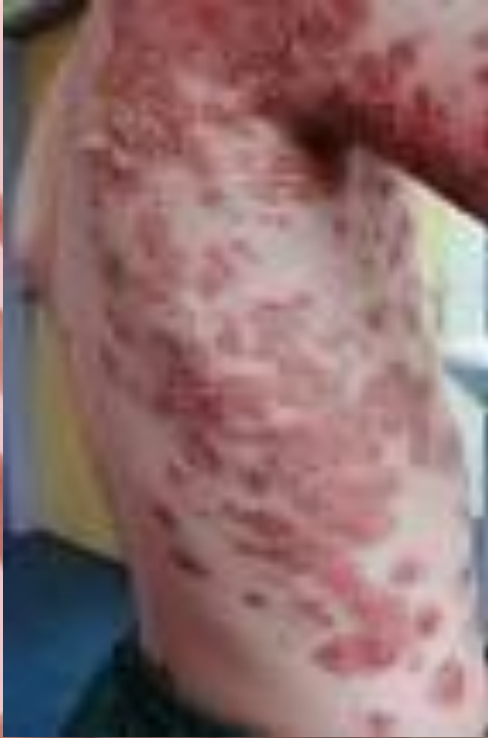Eczema Continuing

- Et:
 - Allergen(s)
 - Diet
 - Cosmetics
 - Soaps
 - Meds
 - Emotional stress
- s/s:
 - Dryness
 - Erythema
 - Edema, itching
 - Crusty, scaling
- Tx:
 - Remove irritant
 - Corticosteroids

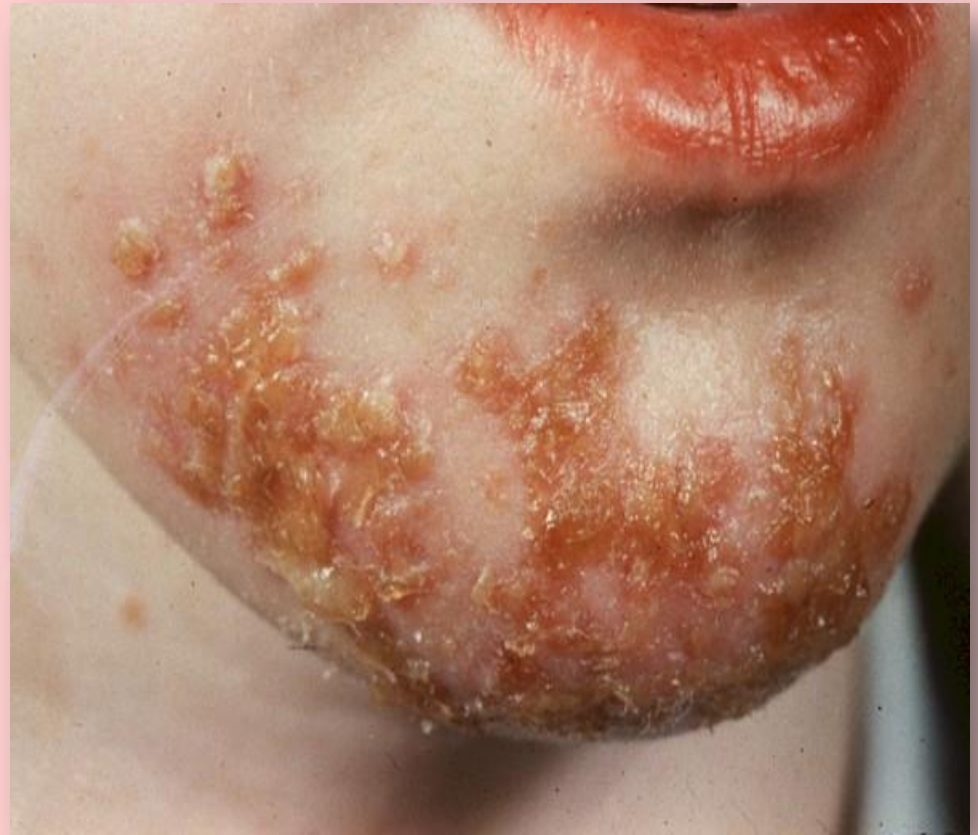

6. Impetigo – A highly contagious skin inf usually caused by streptococci or staphylococci (Et).

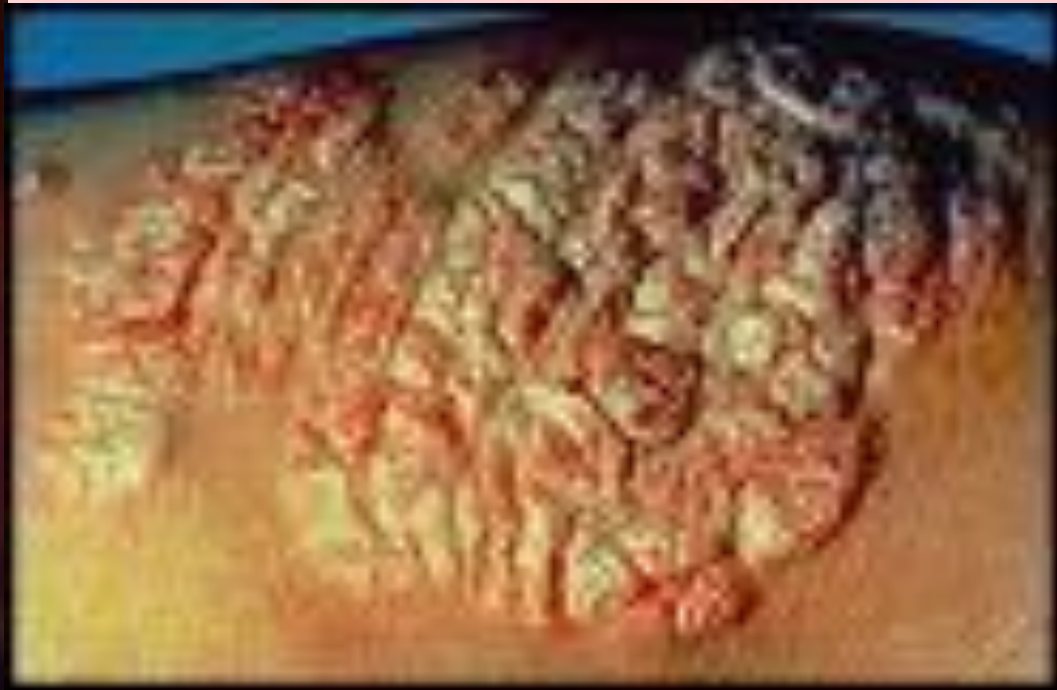
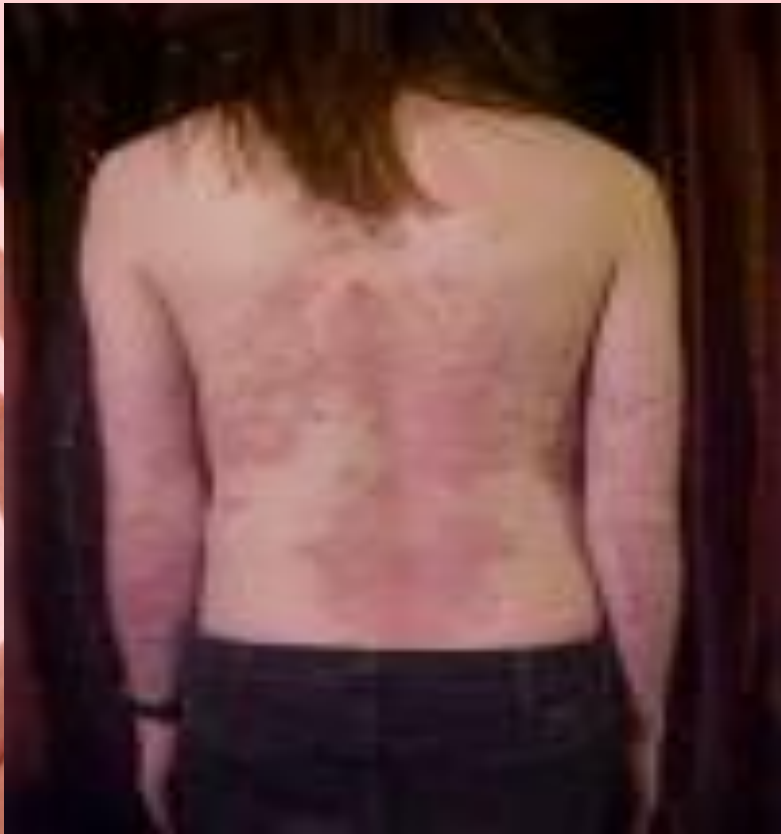
Impetigo Continued

- s/s:
 - Erythema
 - Oozing
 - Yellow crust
- Tx:
 - Wash c/ soap & H2O
 - Keep dry
 - Antibiotics

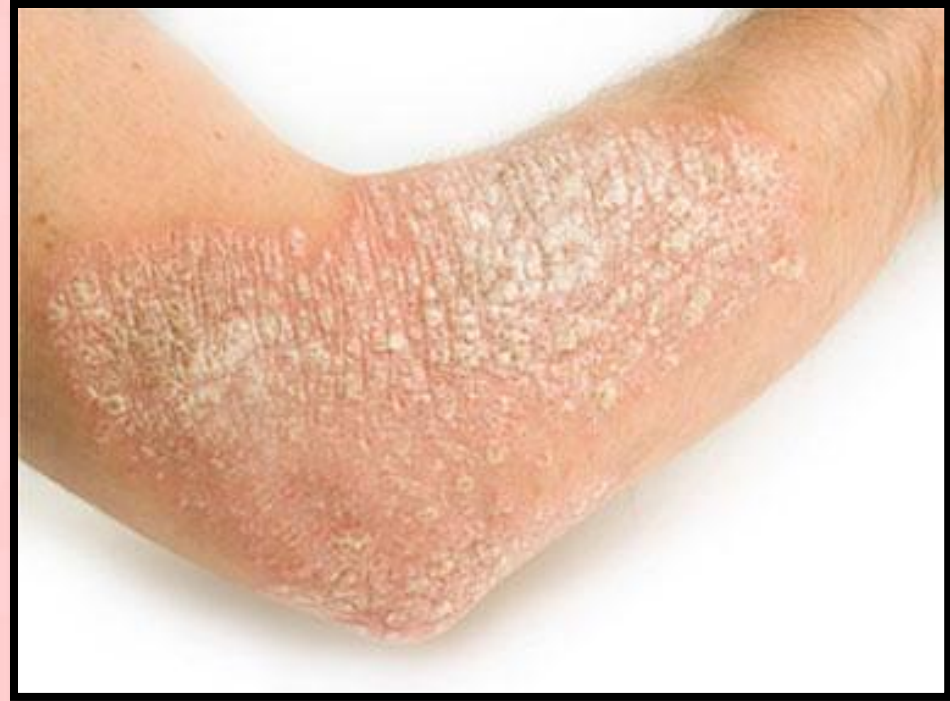

7. Psoriasis – A chronic, noncontagious, genetic skin dz (Et).

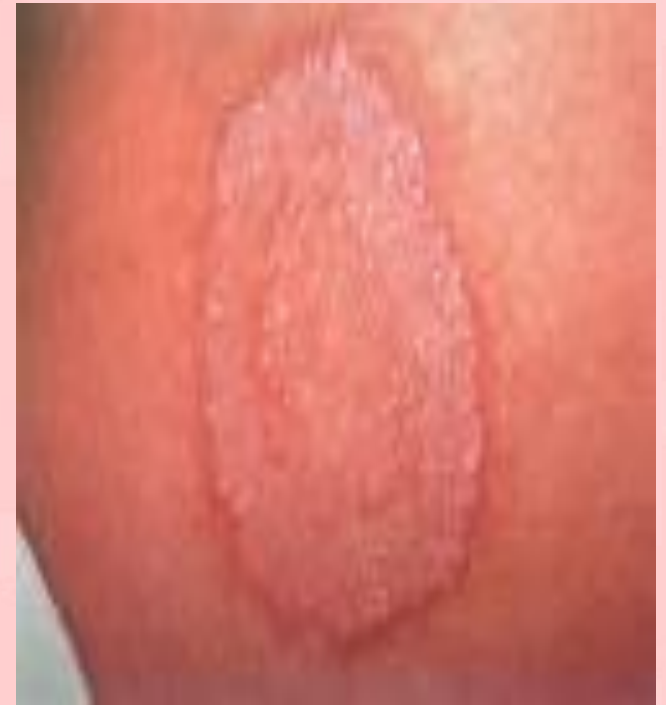
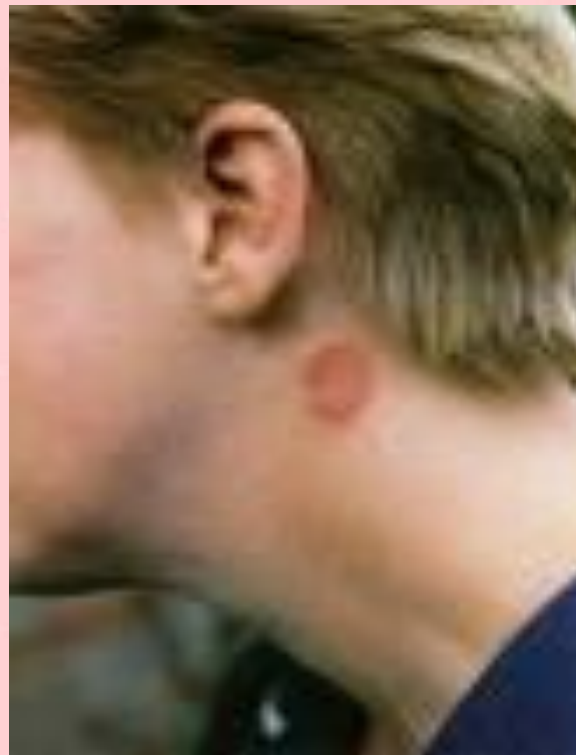
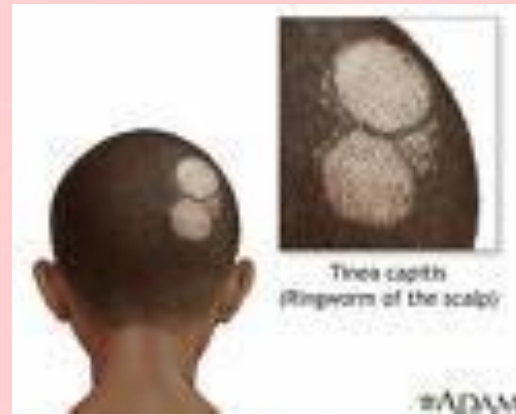Psoriasis Continued

- s/s:
 - Thick, red areas covered with white or silver scales
- Tx:
 - No cure
 - Cortisone ointments
 - UV light txs
 - Removal of scales

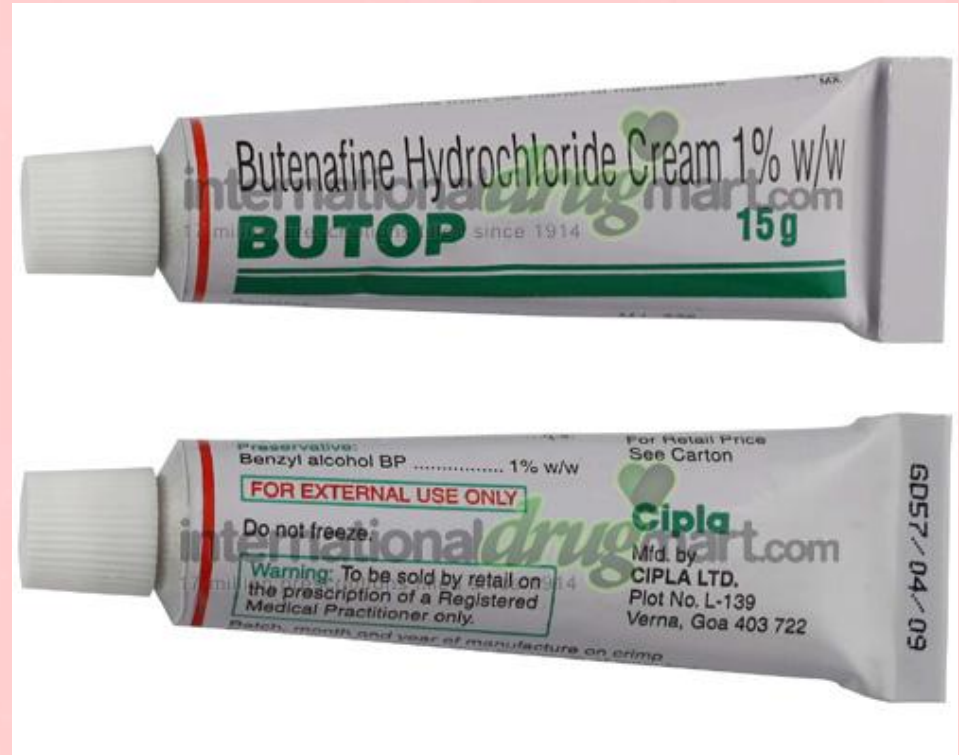

8. Ringworm – A highly contagious fungus inf

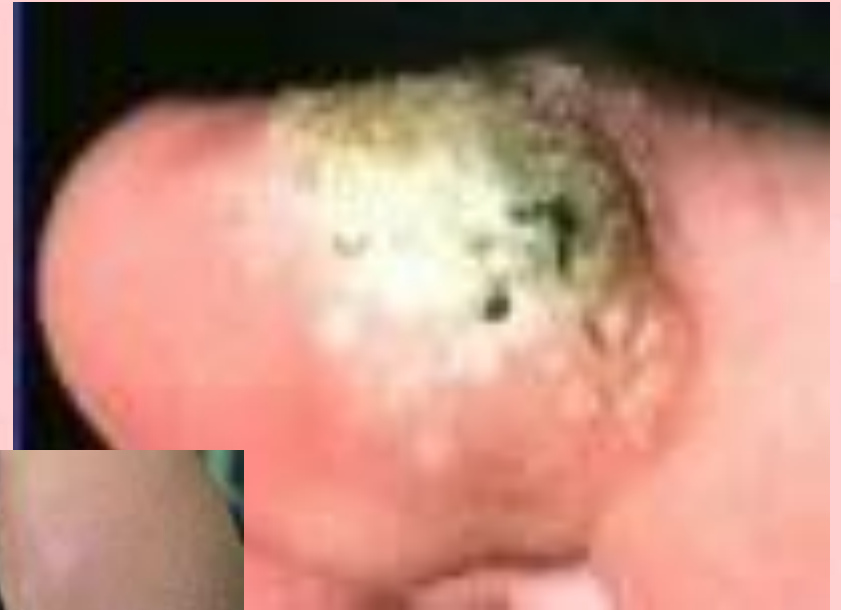
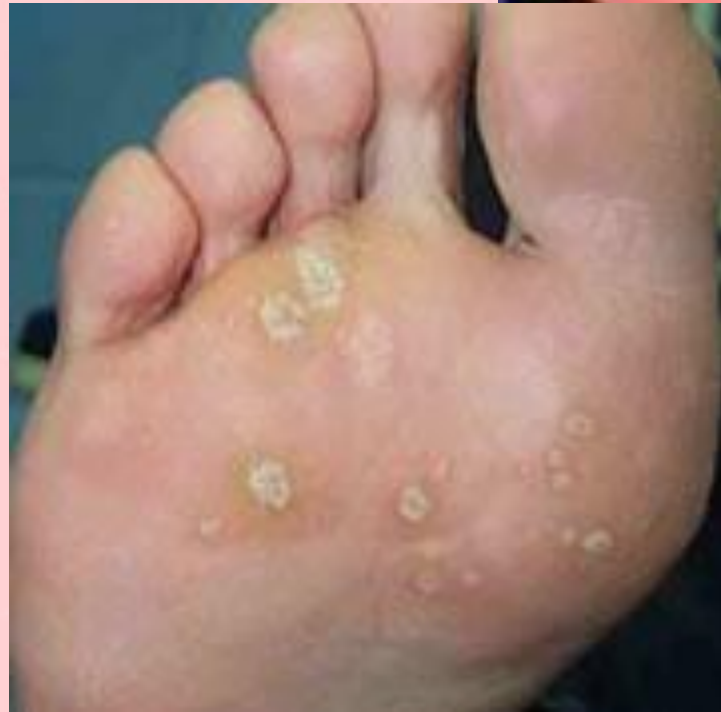
Ringworm Continued

- s/s:
 - Circular area c/ a clear central area surrounded by an itchy, or crusty outer ring.
- Tx:
 - Antifungal medication



9. Verrucae (Warts) – viral inf of the skin.



Warts Continued

- s/s:
 - Hard, rough, elevated, rounded surface
- Tx:
 - Some disappear spontaneously
 - Electricity
 - Liquid nitrogen
 - Acid
 - Chemicals
 - Laser

