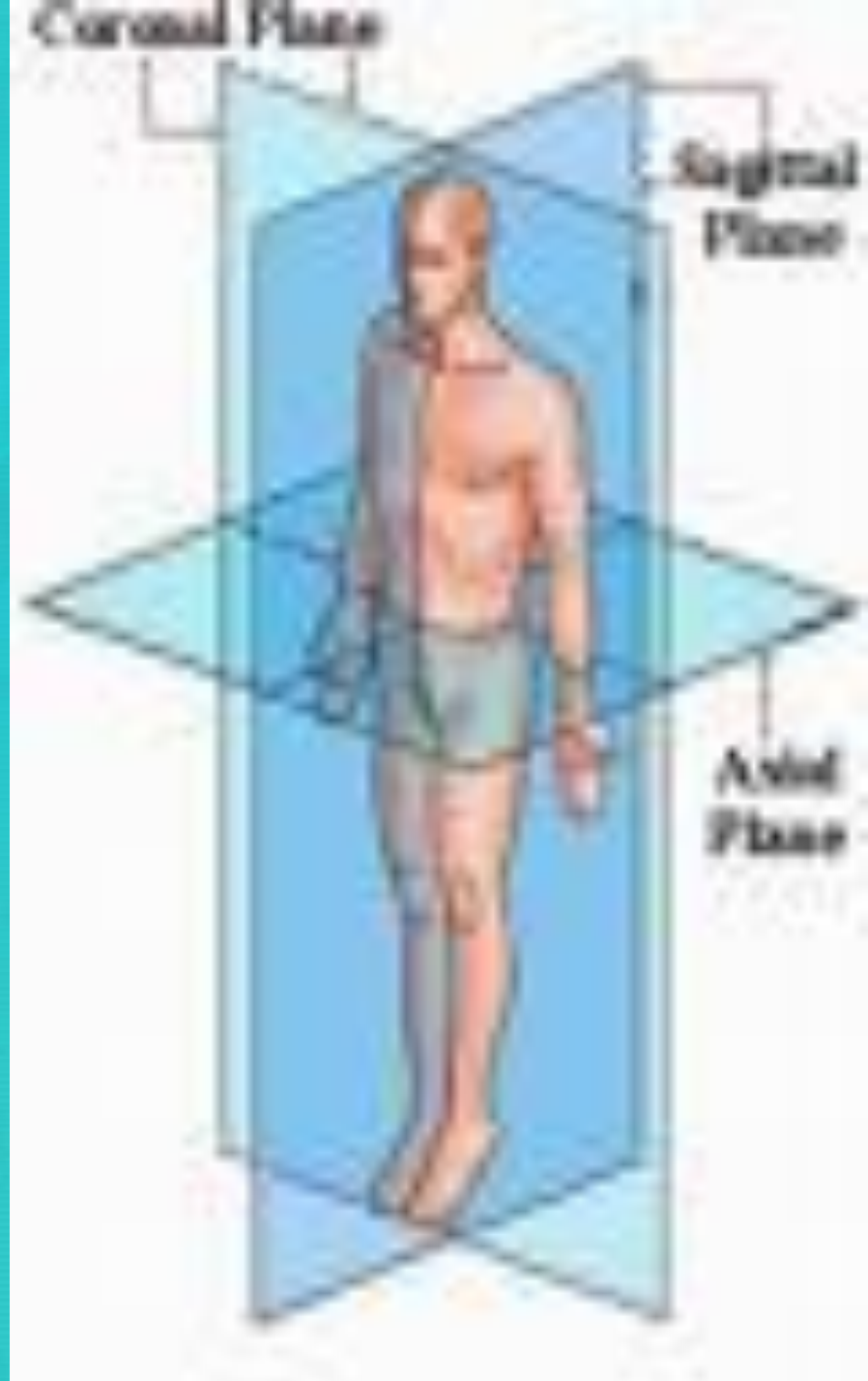


Today's Agenda: 8/25/14

1. Homework Due – Current Event Article #1 by MN.
2. Students will copy A & B List Medical Prefix/Suffix. Quiz on Friday. Remember you may not retake quizzes this year.
3. Students will highlight in notebook syllabus SC Foundation Standard: 1. 2 Recognize body planes, directional terms, quadrants, and cavities.
4. **Table of Contents Unit 1 - TO: Recognize body planes, directional terms, quadrants, and cavities.**
5. Students will partner together to draw planes, directional terms, quadrants, and cavities on life size form.

Body Planes


- Body Planes are imaginary lines drawn through the body at various parts to separate the body into sections.
- There are 3 main body planes, & various directional terms c/in each.



1. Transverse Plane

Divides body into
upper and lower
portions.

Directional
terms c/in:



Superior

(cranial)

Towards the
head



Towards
the feet



Inferior

(caudal)



2. Midsagittal Plane

(Median or Sagittal)


Divides body into equal right and left halves.

Directional terms c/in:




Medial

Towards the midline of the body



Lateral

Away from the
midline of the body



3. Frontal Plane (Coronal)

Divides body into front
and back portions.

**Directional
terms c/in:**



Anterior (Ventral)

On the front of the body



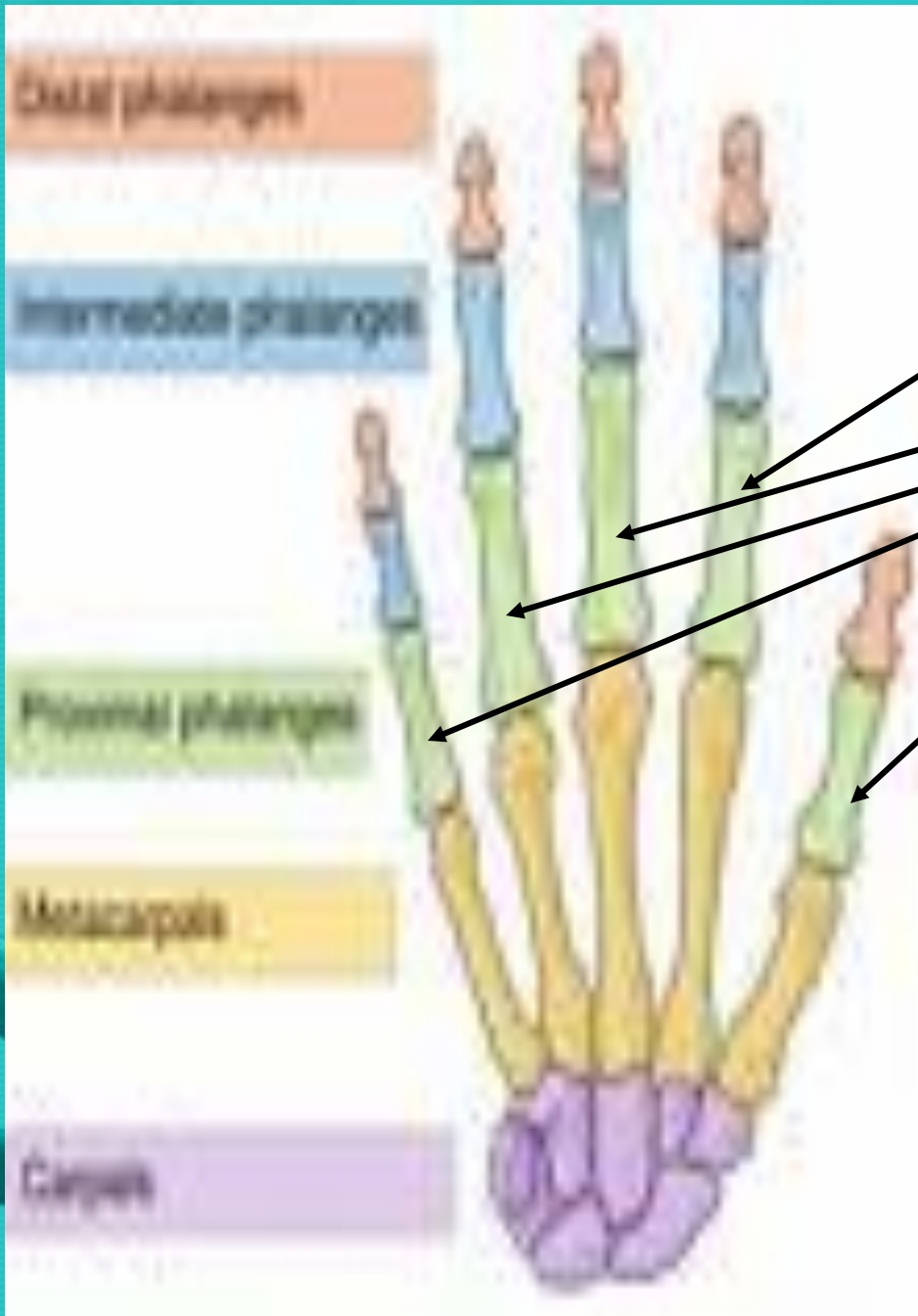
Posterior (Dorsal)

Back part of the body



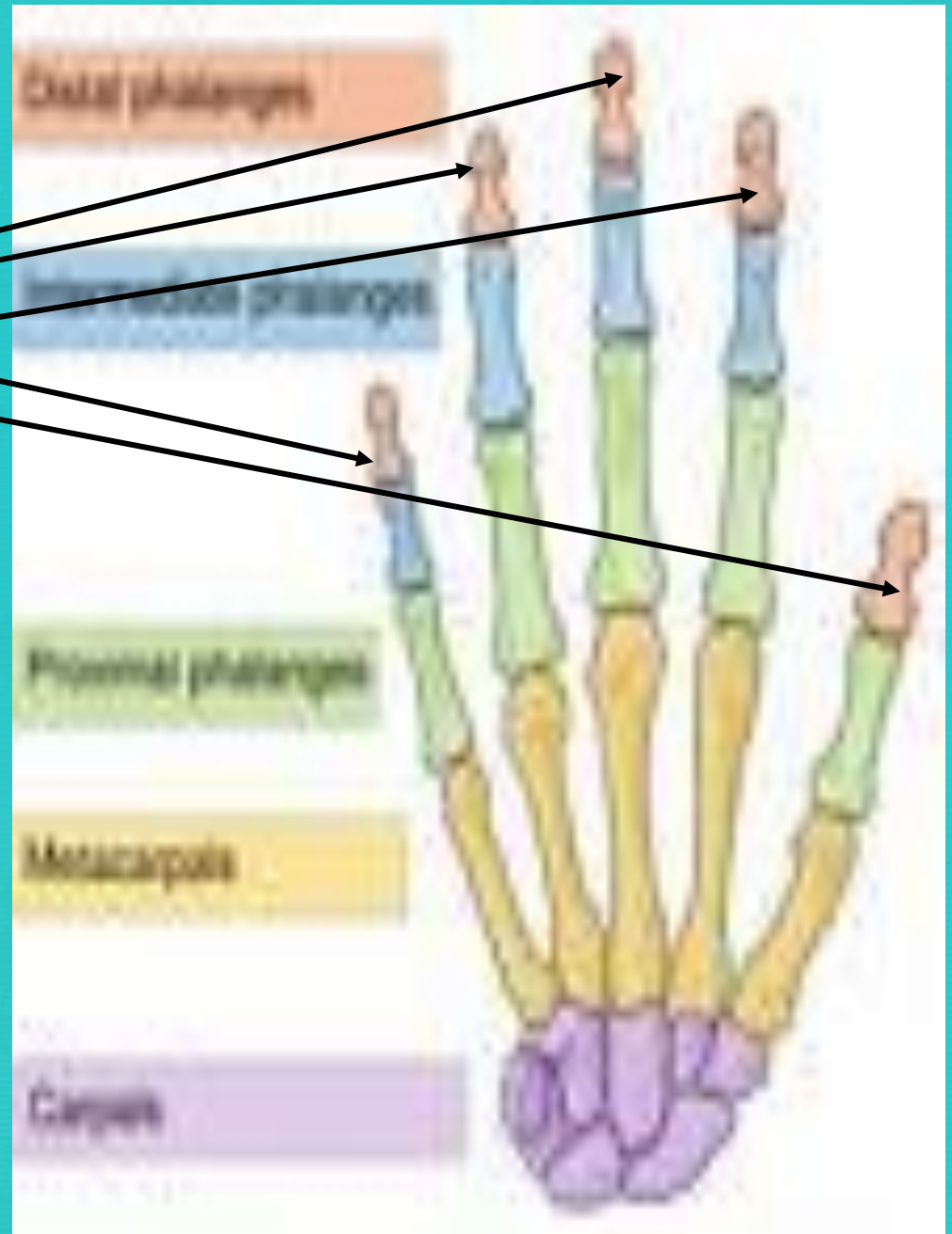
Proximal

Body parts closer to the body/core



Distal

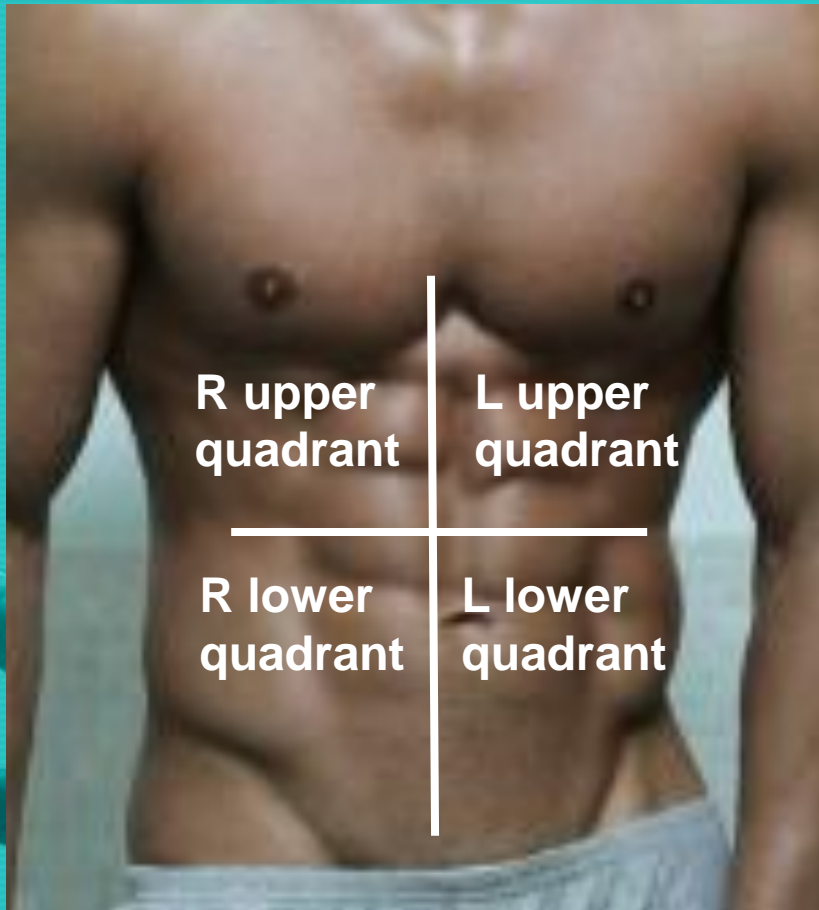
Body parts more distant to the core.



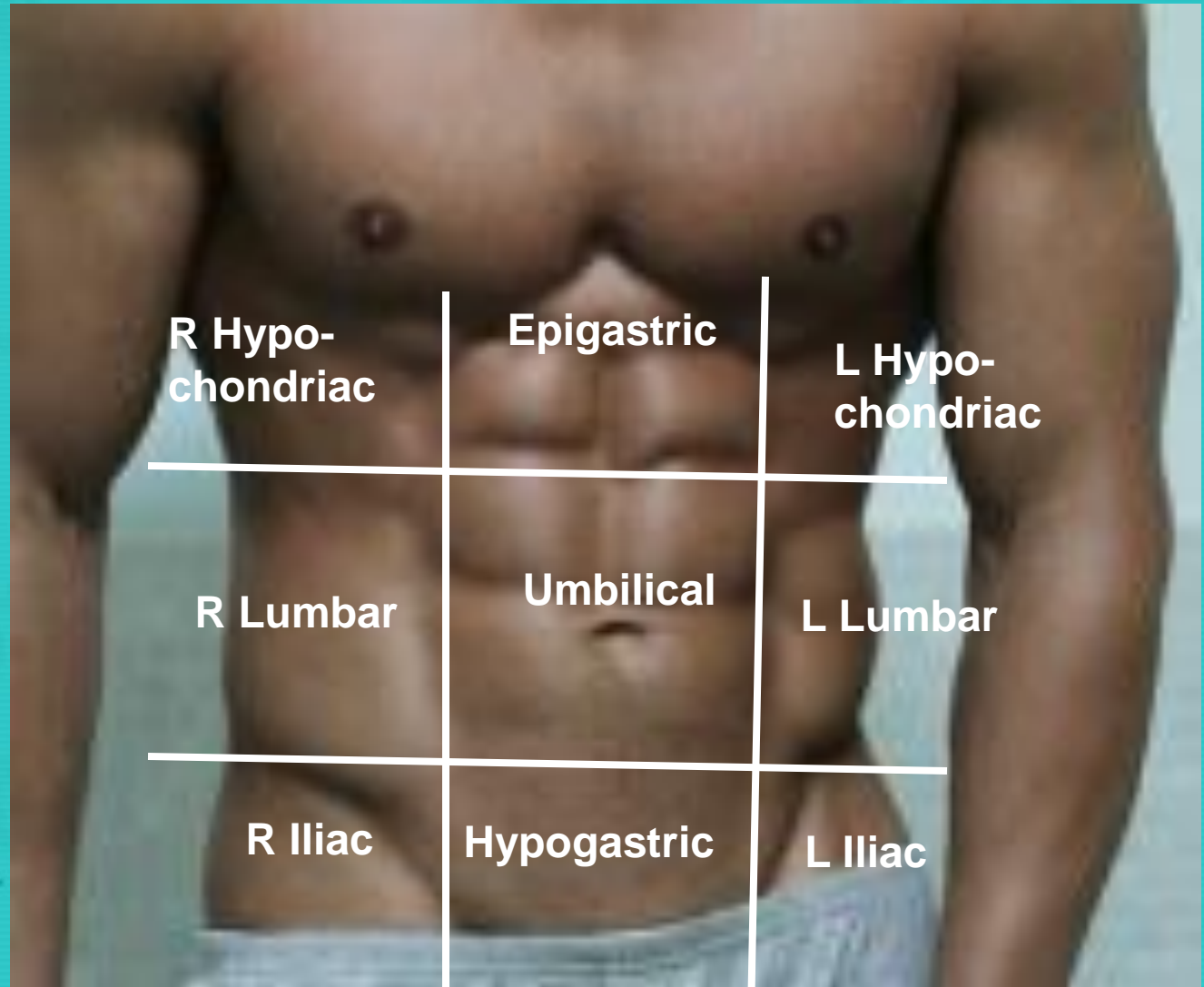
Abdominal Regions:

4 Quadrants

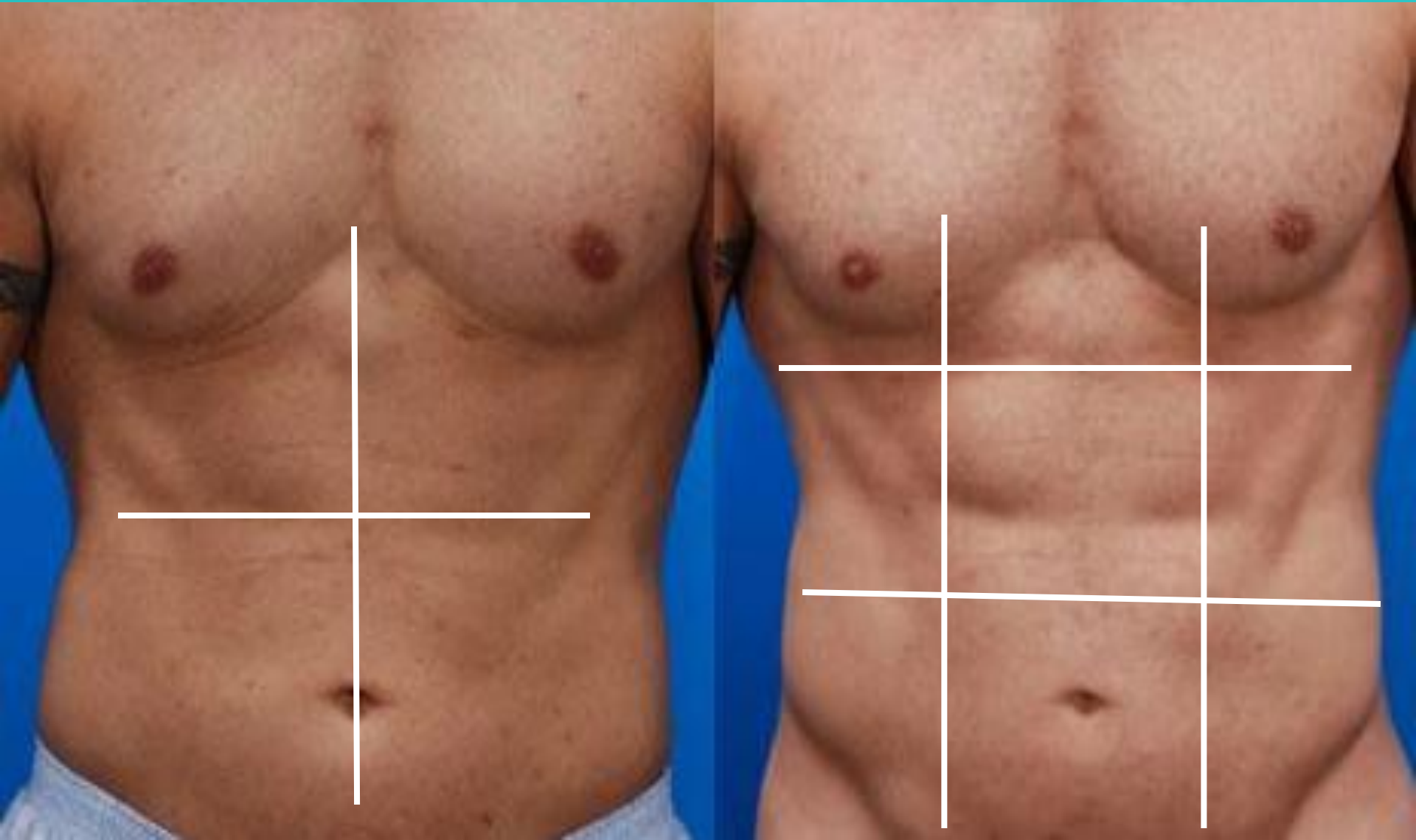9 Regions



9 Regions:

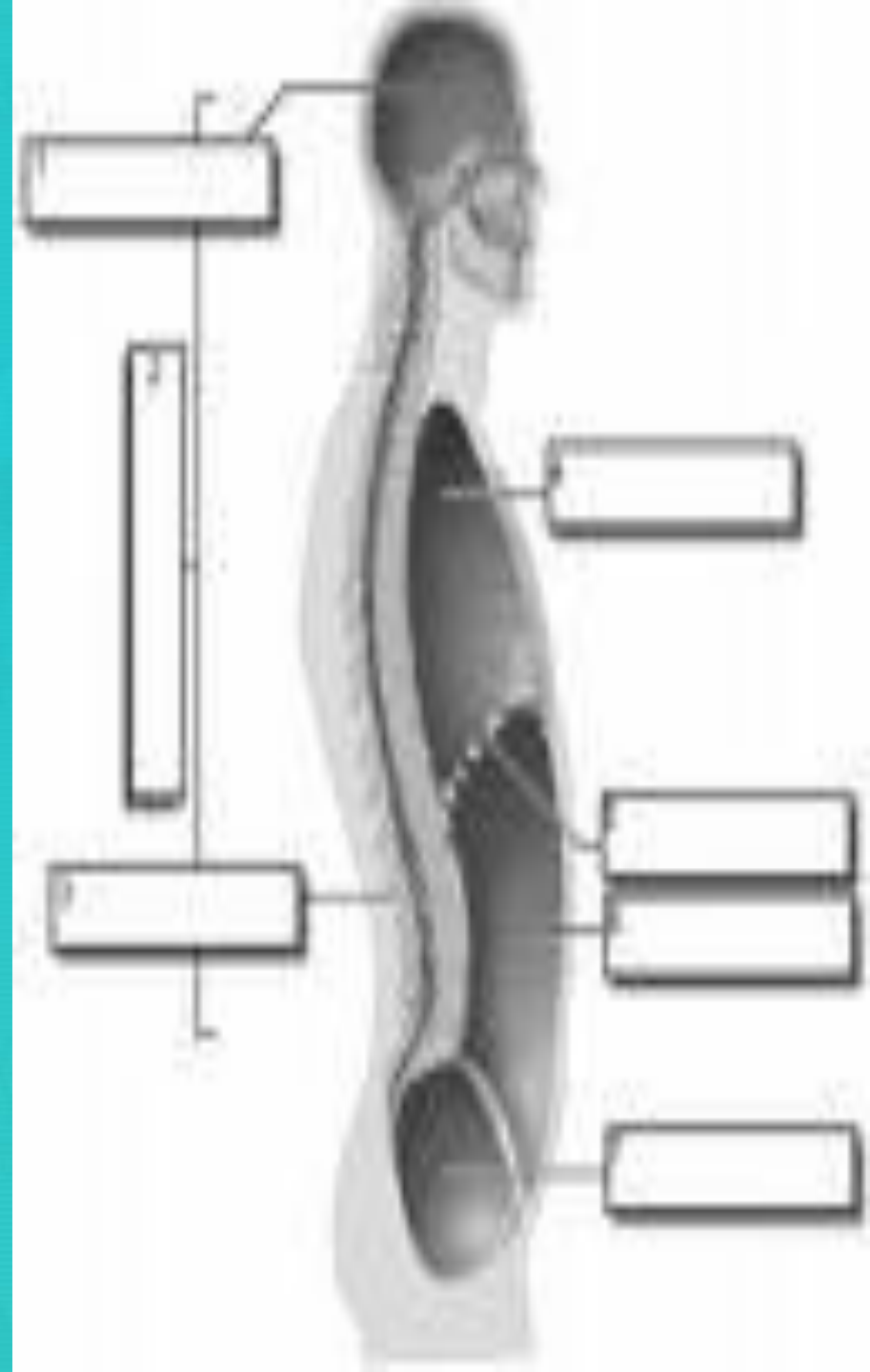


What anatomical structures are c/in each quadrant/region?



Body Cavities

- Spaces c/in the body that contain vital organs.
 - Dorsal
 - Cranial & Spinal
 - Ventral
 - Thoracic
 - Abdominal
 - Pelvic
 - Orbital
 - Nasal
 - Buccal



Closure:

Match the below terms, write each out completely

1. ___ Superior / Cranial

2. ___ Inferior / Caudal

3. ___ Ventral / Anterior

4. ___ Dorsal / Posterior

5. ___ Proximal

6. ___ Distal

7. ___ Medial

8. ___ Lateral

A. Elbow is to the wrist

B. Arms are to the chest

C. Navel is to the chin

D. Heart is to the arm

E. Head is to the
abdomen

F. Patella is to the thigh

G. Sternum is to the
spine

H. Heart is to the
sternum

